



# Test your radiology gut

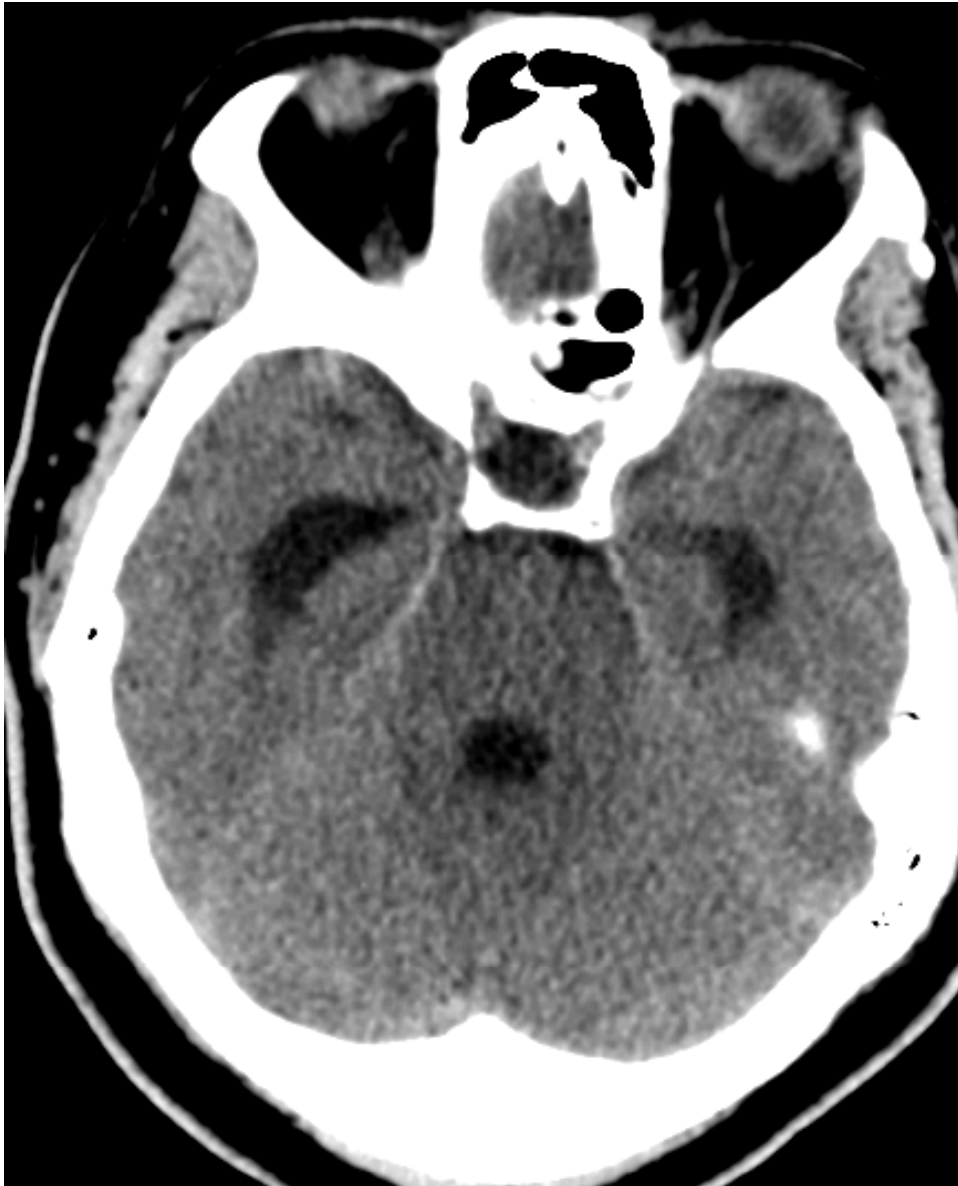
Case 7



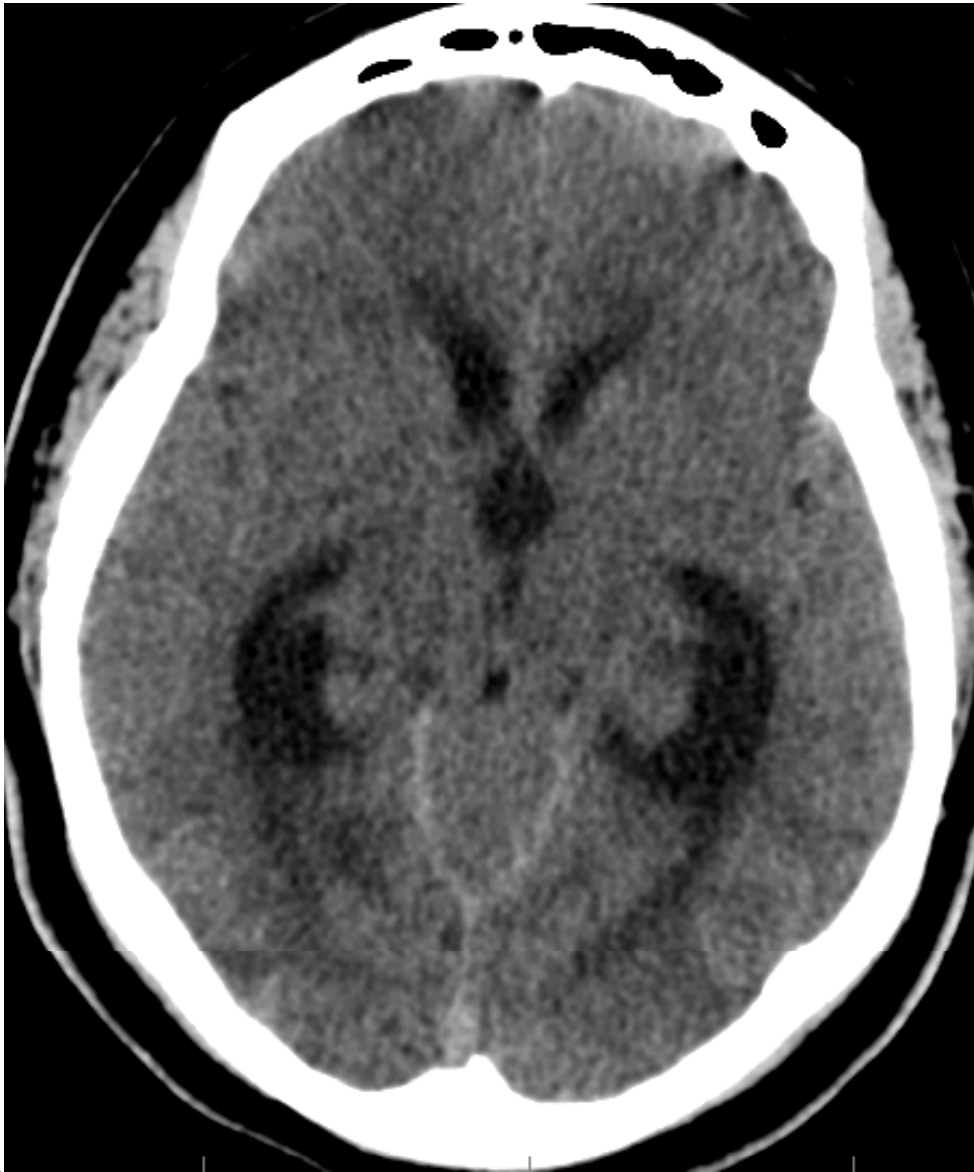
# History

- ▶ 54 Y/O RH AAF who was brought to the ER after being found unresponsive
- ▶ She had history of IVDA and currently on methadone
- ▶ She was seen few days back at the ER and was diagnosed with UTI
- ▶ There was no weakness, numbness or vertigo per the family

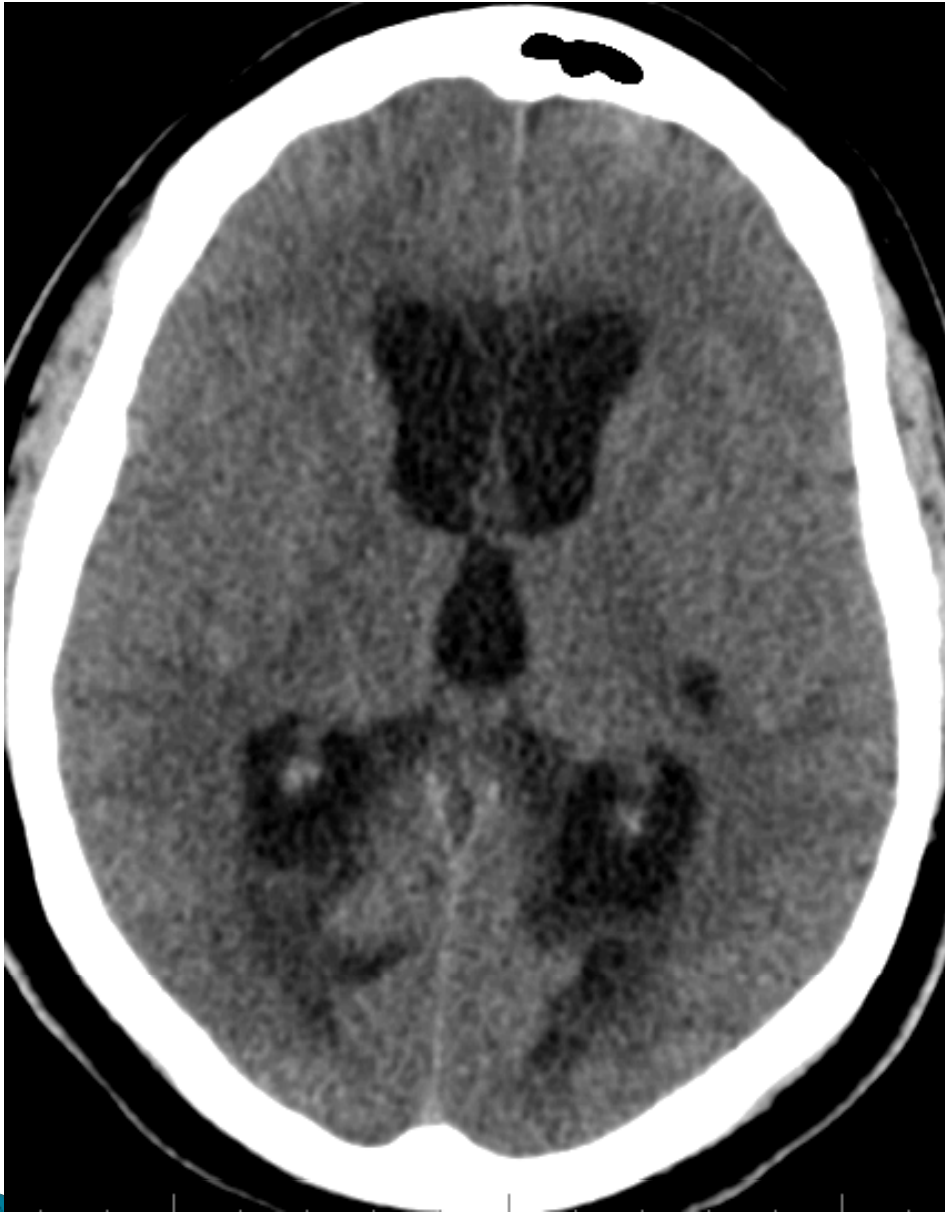



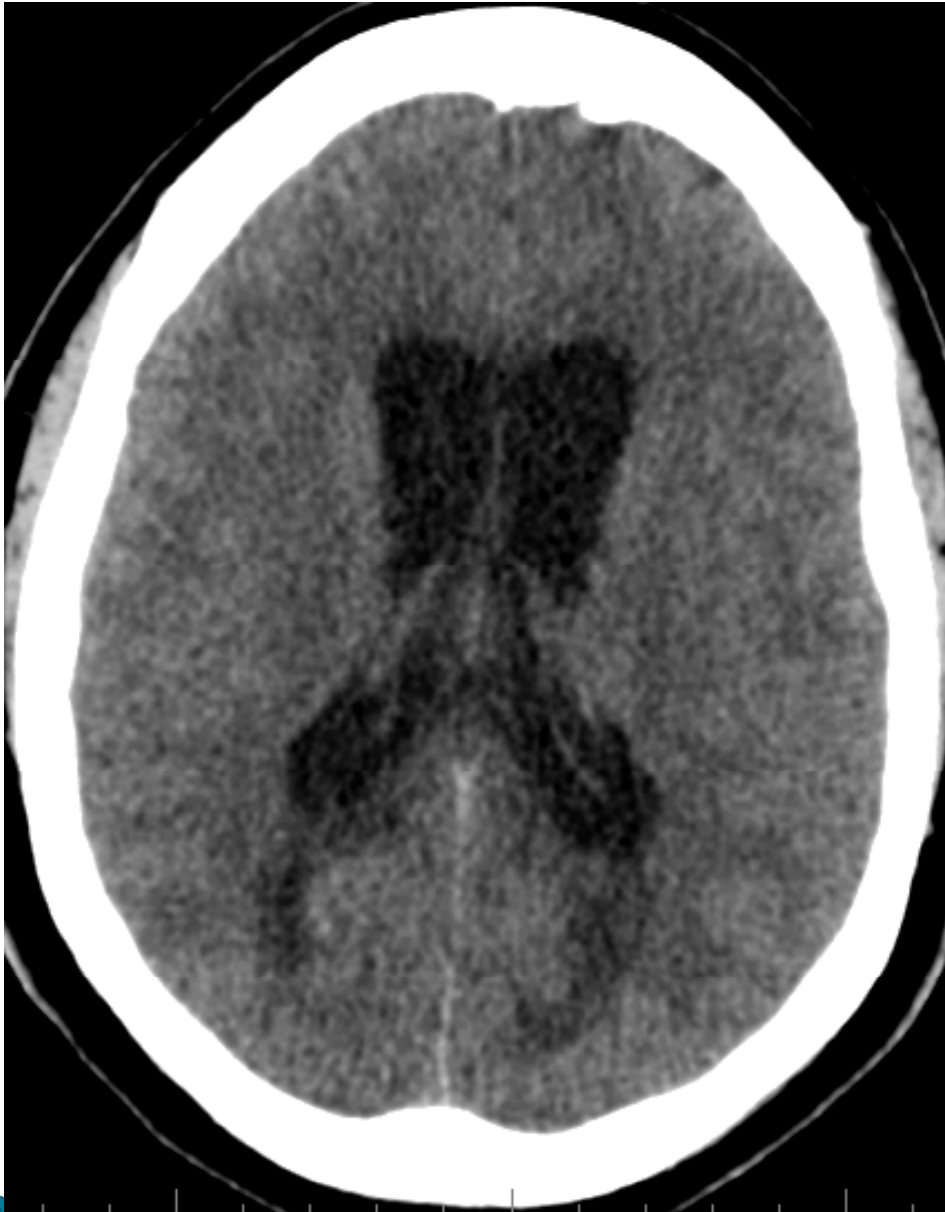- Axial CT head W/O contrast



- Axial CT head W/O contrast



- Axial CT head W/O contrast



- Axial CT head W/O contrast

- ▶ Describe the finding on the image and possible etiology.
- ▶ Email answers to [mrayes@med.wayne.edu](mailto:mrayes@med.wayne.edu)

